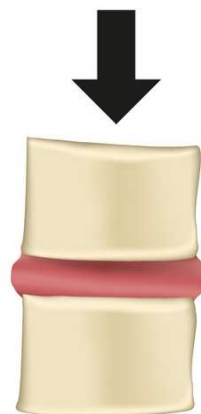
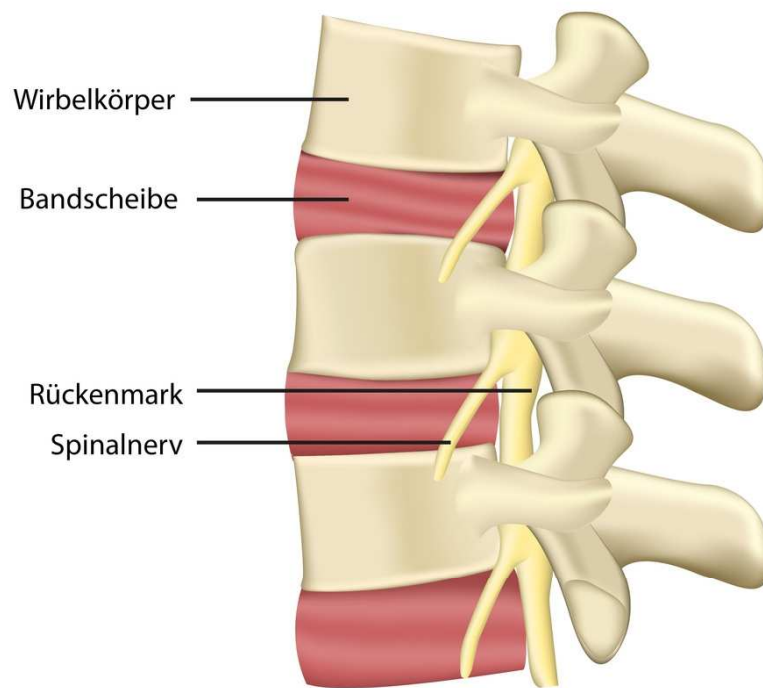
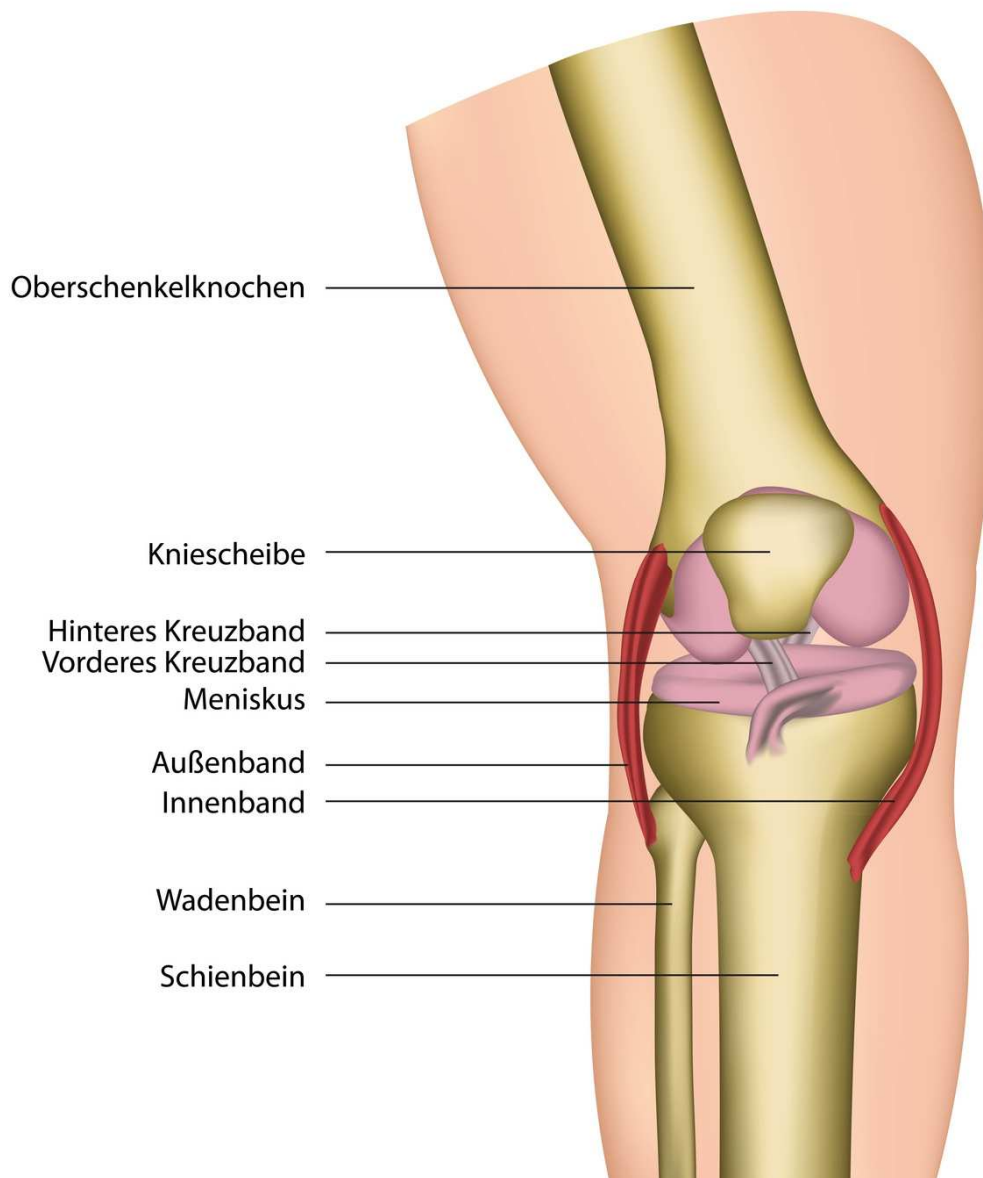


Wirbelsäule



© bilderzweig – Fotolia.com

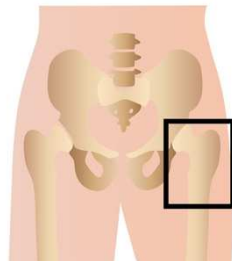
Kniegelenk



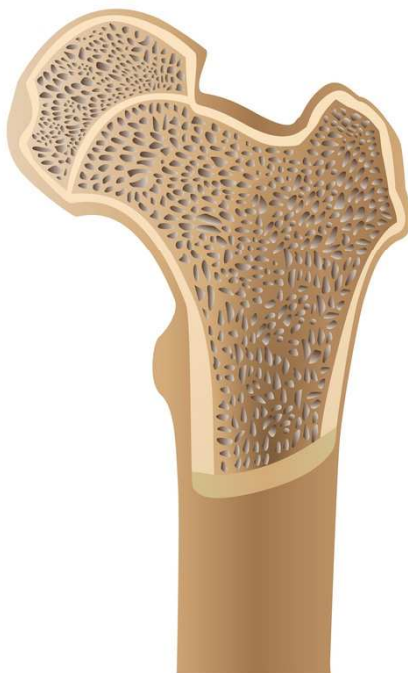© bilderzweig – Fotolia.com

<http://www.aok-bw.de/orthopaedie>

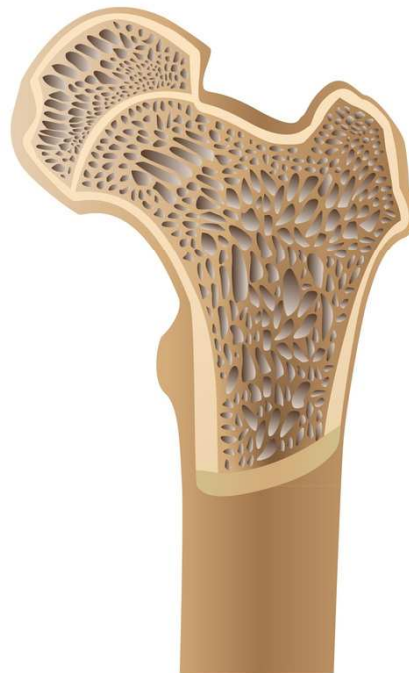Osteoporose



Osteoporose (Knochenschwund)



Normaler Knochen

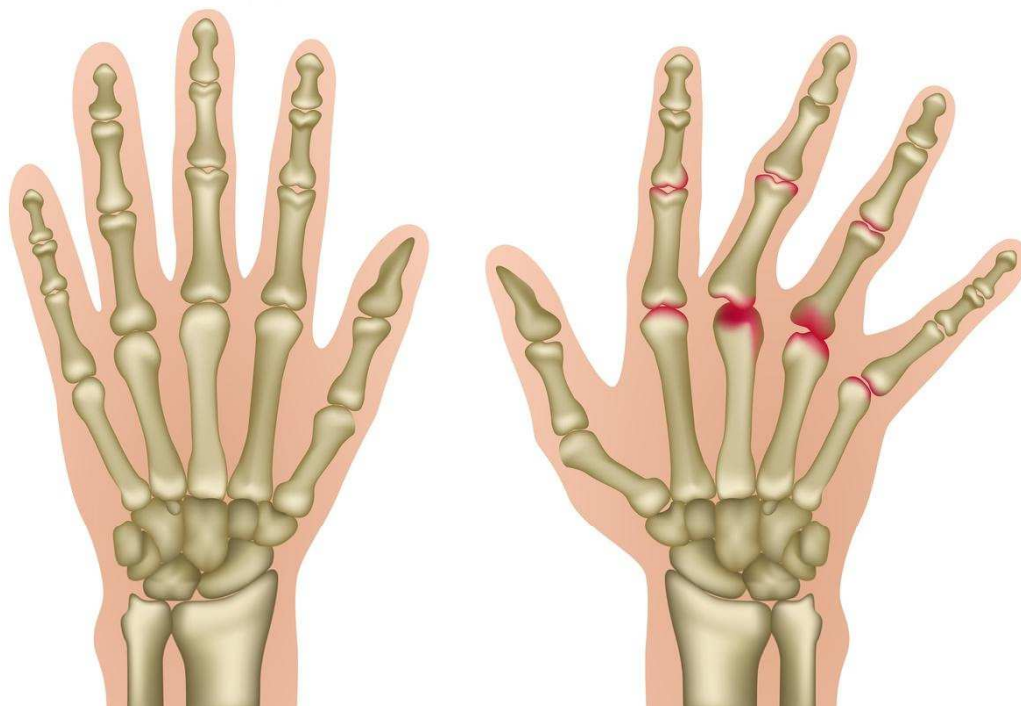


Knochen mit
Osteoporose

© bilderzweig – Fotolia.com

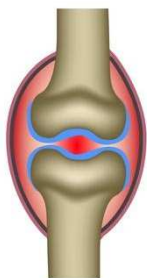
<http://www.aok-bw.de/orthopaedie>

Rheumatoide Arthritis

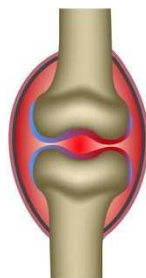



Gesunde Knochen

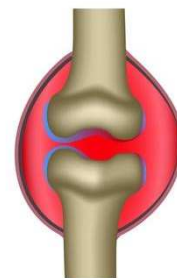

Hand mit rheumatoider Arthritis



1. Gelenkentzündung



2. An der Gelenkinnenhaut entsteht ein geschwulstartiges Gewebe.



3. Knorpel und Knochen werden mit der Zeit zerstört. Die Gelenkkapsel schwillt an.

© bilderzweig – Fotolia.com